The Pharynx

The pharynx is situated behind the nasal cavities, the mouth, and the larynx and may be divided into **nasal, oral,** and **laryngeal parts.** The pharynx is funnel shaped, its upper, wider end lying under the skull and its lower, narrow end becoming continuous with the esophagus opposite the 6th cervical vertebra. The pharynx has a musculomembranous wall, which is deficient anteriorly. Here, it is replaced by the posterior openings into the nose, the opening into the mouth, and the inlet of the larynx. By means of the auditory tube, the mucous membrane is also continuous with that of the tympanic cavity.

Muscles of the Pharynx

The muscles in the wall of the pharynx consist of the **superior, middle, and inferior constrictor muscles**, whose fibers run in a somewhat circular direction, and the **stylopharyngeus** and **salpingopharyngeus muscles,** whose fibers run in a somewhat longitudinal direction.

The three constrictor muscles extend around the pharyngeal wall to be inserted into a fibrous band or raphe that extends from the pharyngeal tubercle on the basilar part of the occipital bone of the skull down to the esophagus. The three constrictor muscles overlap each other so that the middle constrictor lies on the outside of the lower part of the superior constrictor and the inferior constrictor lies outside the lower part of the middle constrictor.

The lower part of the inferior constrictor, which arises from the cricoid cartilage, is called the **cricopharyngeus muscle**. The fibers of the cricopharyngeus pass horizontally around the lowest and narrowest part of the pharynx and act as a sphincter. **Killian's dehiscence** is the area on the posterior pharyngeal wall between the upper propulsive part of the inferior constrictor and the lower sphincteric part, the cricopharyngeus.

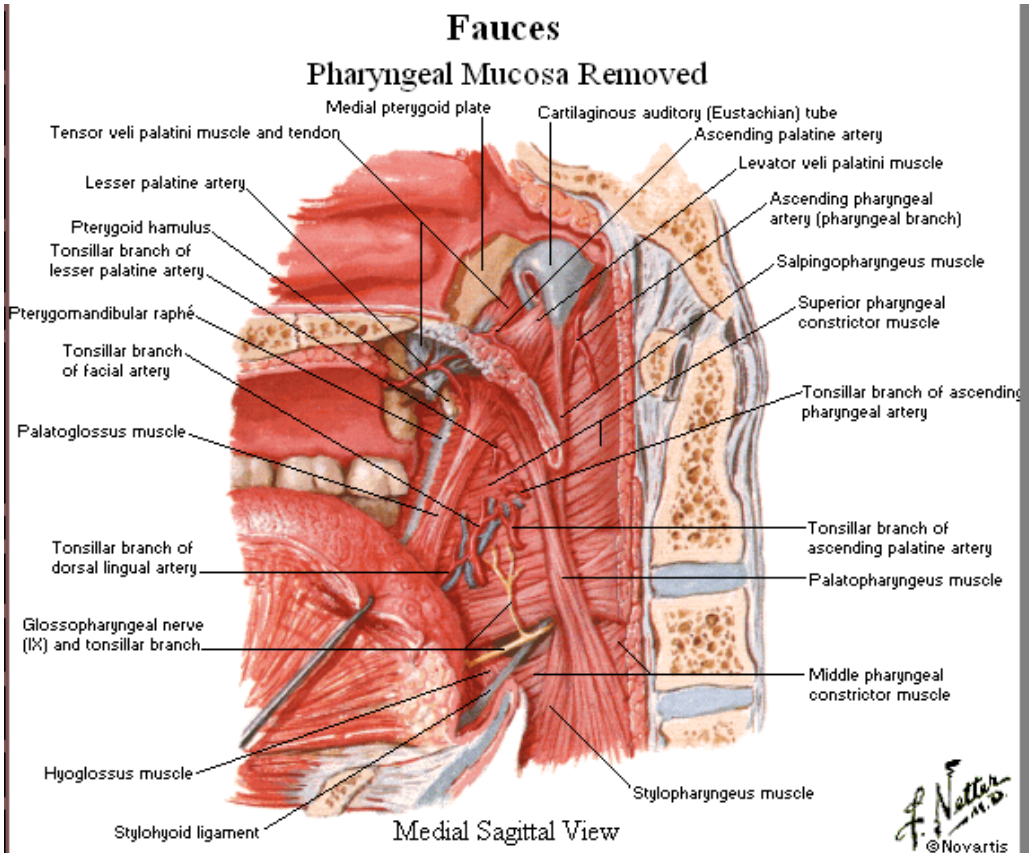
Fauces
Pharyngeal Mucosa Removed
Medial pterygoid plate
Cartilaginous auditory (Eustachian) tube
Tensor veli palatini muscle and tendon
Ascending palatine artery
Levator veli palatini muscle
Lesser palatine artery
Ascending pharyngeal artery (pharyngeal branch)
Pterygoid hamulus
Tonsillar branch of lesser palatine artery
Salpingopharyngeus muscle
Pterygomandibular raphé
Superior pharyngeal constrictor muscle
Tonsillar branch of facial artery
Tonsillar branch of ascending pharyngeal artery
Palatoglossus muscle
Tonsillar branch of ascending palatine artery
Tonsillar branch of dorsal lingual artery
Palatopharyngeus muscle
Glossopharyngeal nerve (IX) and tonsillar branch
Middle pharyngeal constrictor muscle
Hyoglossus muscle
Stylopharyngeus muscle
Stylohyoid ligament
Medial Sagittal View
©Novartis

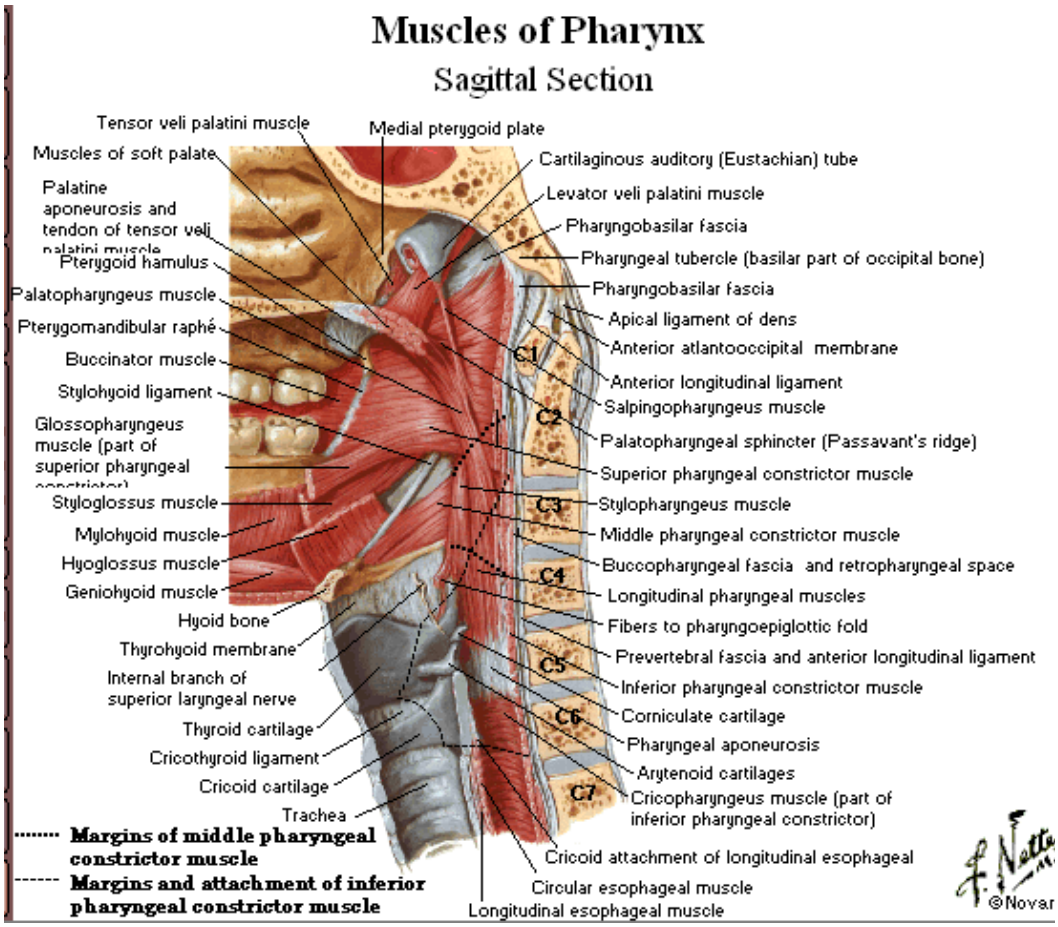
Muscles of Pharynx
Sagittal Section
Tensor veli palatini muscle
Medial pterygoid plate
Muscles of soft palate
Cartilaginous auditory (Eustachian) tube
Palatine aponeurosis and tendon of tensor veli palatini muscle
Levator veli palatini muscle
Pharyngobasilar fascia
Pterygoid hamulus
Pharyngeal tubercle (basilar part of occipital bone)
Palatopharyngeus muscle
Pharyngobasilar fascia
Pterygomandibular raphé
Apical ligament of dens
Anterior atlantooccipital membrane
Buccinator muscle
Anterior longitudinal ligament
Stylohyoid ligament
Salpingopharyngeus muscle
Glossopharyngeus muscle (part of superior pharyngeal constrictor)
Palatopharyngeal sphincter (Passavant's ridge)
Superior pharyngeal constrictor muscle
Styloglossus muscle
Stylopharyngeus muscle
Mylohyoid muscle
Middle pharyngeal constrictor muscle
Hyoglossus muscle
Buccopharyngeal fascia and retropharyngeal space
Geniohyoid muscle
Longitudinal pharyngeal muscles
Hyoid bone
Fibers to pharyngoepiglottic fold
Thyrohyoid membrane
Prevertebral fascia and anterior longitudinal ligament
Internal branch of superior laryngeal nerve
Inferior pharyngeal constrictor muscle
Thyroid cartilage
Corniculate cartilage
Cricothyroid ligament
Pharyngeal aponeurosis
Cricoid cartilage
Arytenoid cartilages
Trachea
Cricopharyngeus muscle (part of inferior pharyngeal constrictor)
C1
C2
C3
C4
C5
C6
C7
Margins of middle pharyngeal constrictor muscle
Margins and attachment of inferior pharyngeal constrictor muscle
Cricoid attachment of longitudinal esophageal
Circular esophageal muscle
Longitudinal esophageal muscle
©Novar

Pharynx divisions

The pharynx is divided into three parts: the nasal pharynx, the oral pharynx, and the laryngeal pharynx.

Nasal Pharynx

This lies above the soft palate and behind the nasal cavities. In the submucosa of the roof is a collection of lymphoid tissue called the **pharyngeal tonsil**. The pharyngeal isthmus is the opening in the floor between the soft palate and the posterior pharyngeal wall. On the lateral wall is the opening of the **auditory tube,** the elevated ridge of which is called the **tubal elevation**. The **pharyngeal recess** is a depression in the pharyngeal wall behind the tubal elevation. The **salpingopharyngeal fold** is a vertical fold of mucous membrane covering the salpingopharyngeus muscle.

Oral Pharynx

This lies behind the oral cavity. The floor is formed by the posterior one third of the tongue and the interval between the tongue and epiglottis. In the midline is the **median glossoepiglottic fold**, and on each side the **lateral glossoepiglottic fold.** The depression on each side of the median glossoepiglottic fold is called the **vallecula**.
On the lateral wall on each side are the palatoglossal and the palatopharyngeal arches or folds and the palatine tonsils between them. The palatoglossal arch is a fold of mucous membrane covering the palatoglossus muscle. The interval between the two palatoglossal arches is called the **oropharyngeal isthmus** and marks the boundary between the mouth and pharynx. The palatopharyngeal arch is a fold of mucous membrane covering the palatopharyngeus muscle. The recess between the palatoglossal and palatopharyngeal arches is occupied by the **palatine tonsil.**

Laryngeal Pharynx

This lies behind the opening into the larynx. The lateral wall is formed by the thyroid cartilage and the thyrohyoid membrane. The **piriform fossa** is a depression in the mucous membrane on each side of the laryngeal inlet.

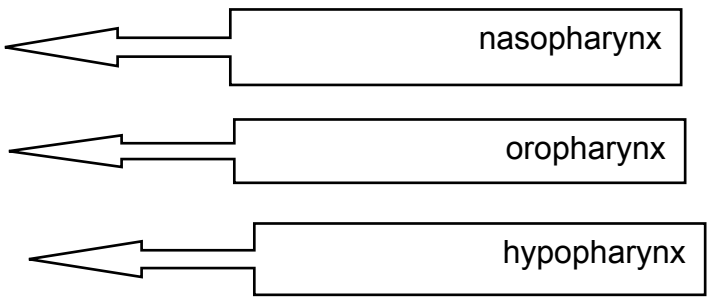

Pharynx
Sagittal Section

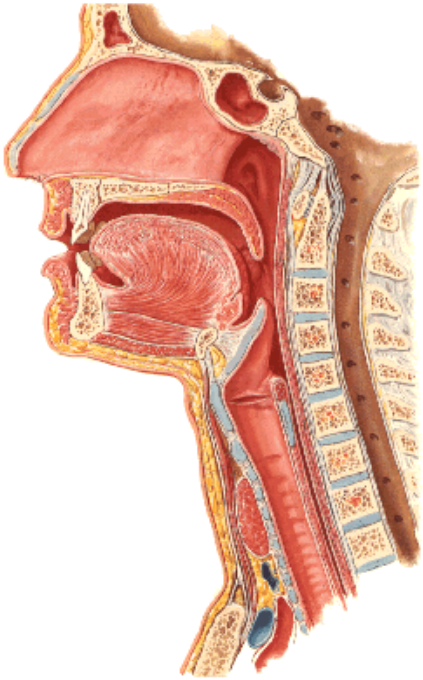

Pharynx
Opened Posterior View

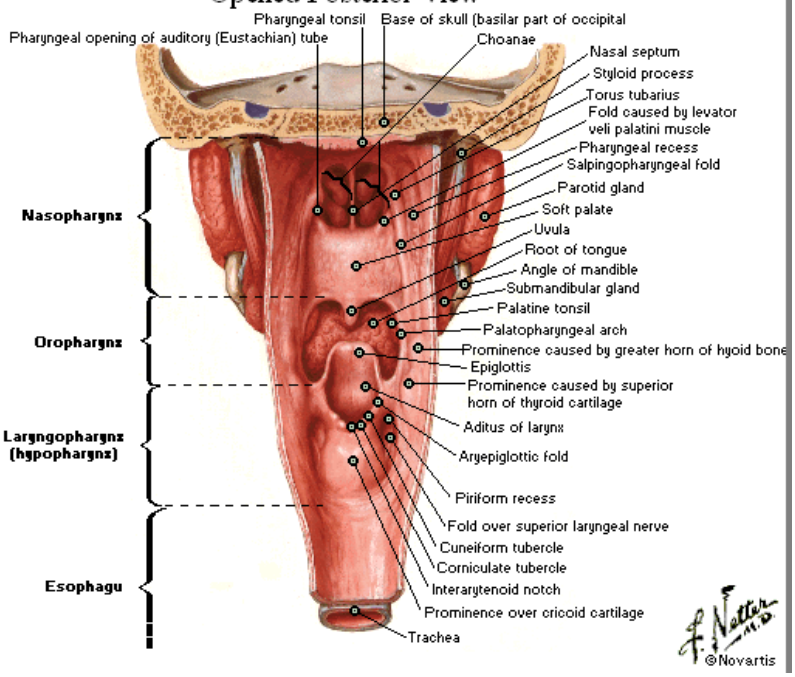

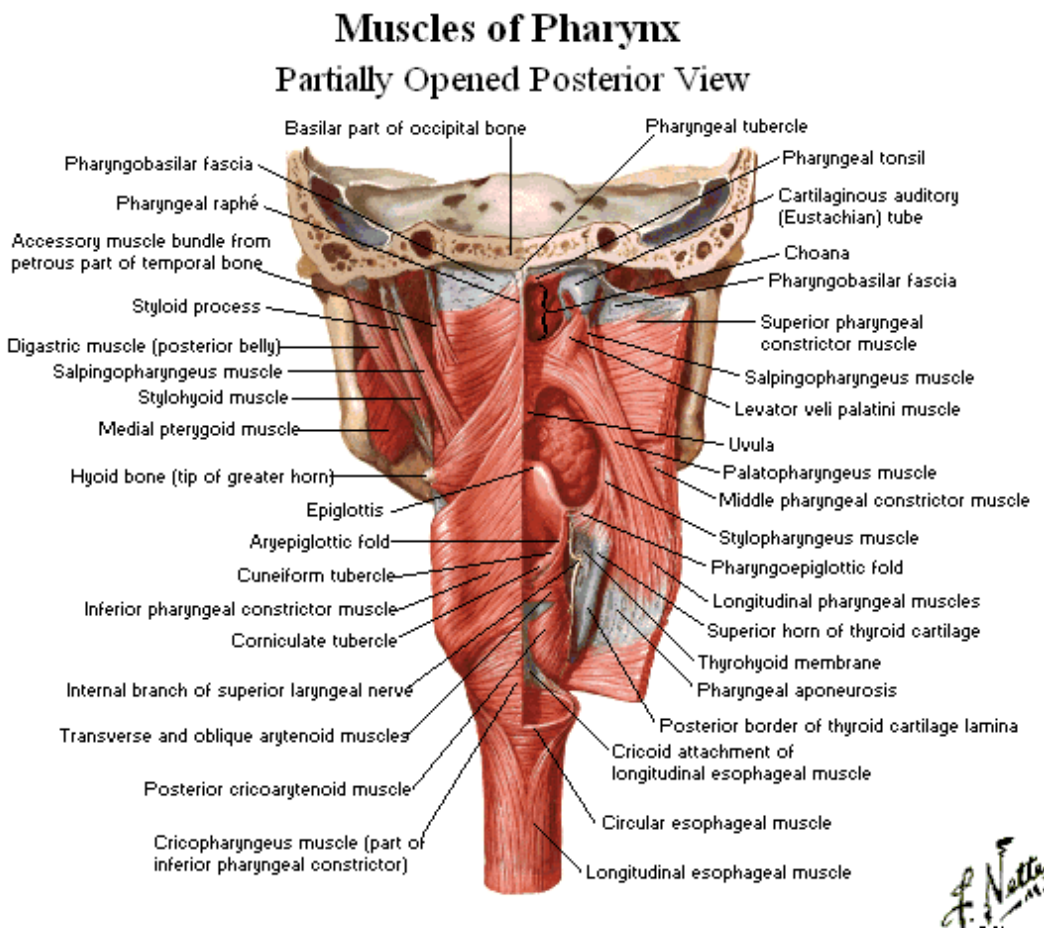

Sensory Nerve Supply of the Pharyngeal

Mucous Membrane

Nasal pharynx: The maxillary nerve (V2)

Oral pharynx: The glossopharyngeal nerve

Laryngeal pharynx (around the entrance into the larynx): The internal laryngeal branch of the vagus nerve

Blood Supply of the Pharynx

Ascending pharyngeal, tonsillar branches of facial arteries, and branches of maxillary and lingual arteries

Lymph Drainage of the Pharynx

Directly into the deep cervical lymph nodes or indirectly via the retropharyngeal or paratracheal nodes into the deep cervical nodes

Palatine Tonsils

The palatine tonsils are two masses of lymphoid tissue, each located in the depression on the lateral wall of the oral part of the pharynx between the palatoglossal and palatopharyngeal arches. Each tonsil is covered by mucous membrane, and its free medial surface projects into the pharynx. The surface is pitted by numerous small openings that lead into the **tonsillar crypts.** The tonsil is covered on its lateral surface by a **fibrous capsule**. The capsule is separated from the superior constrictor muscle by loose areolar tissue.

The tonsil reaches its maximum size during early childhood, but after puberty it diminishes considerably in size.

Blood Supply

The tonsillar branch of the facial artery. The veins pierce the superior constrictor muscle and join the external palatine, the pharyngeal, or the facial veins.

Lymph Drainage of the Tonsil

The upper deep cervical lymph nodes, just below and behind the angle of the mandible.

Waldeyer's Ring of Lymphoid Tissue

The lymphoid tissue that surrounds the opening into the respiratory and digestive systems forms a ring. The lateral part of the ring is formed by the palatine tonsils and tubal tonsils (lymphoid tissue around the opening of the auditory tube in the lateral wall of the nasopharynx).

The pharyngeal tonsil in the roof of the nasopharynx forms the upper part, and the lingual tonsil on the posterior third of the tongue forms the lower part.

Muscle	Origin	Insertion	Nerve Supply	Action
Superior constrictor	Medial pterygoid plate, pterygoid hamulus, pterygomandibular ligament, mylohyoid line of mandible	Pharyngeal tubercle of occipital bone, raphe in midline posteriorly	Pharyngeal plexus	Aids soft palate in closing off nasal pharynx, propels bolus downward
Middle constrictor	Lower part of stylohyoid ligament, lesser and greater cornu of hyoid bone	Pharyngeal raphe	Pharyngeal plexus	Propels bolus downward
Inferior constrictor	Lamina of thyroid cartilage, cricoid cartilage	Pharyngeal raphe	Pharyngeal plexus	Propels bolus downward
Cricopharyngeus	Lowest fibers of inferior constrictor muscle			Sphincter at lower end of pharynx
Stylopharyngeus	Styloid process of temporal bone	Posterior border of thyroid cartilage	Glossopharyngeal nerve	Elevates larynx during swallowing
Salpingopharyngeus	Auditory tube	Blends with palatopharyngeus	Pharyngeal plexus	Elevates pharynx
Palatopharyngeus	Palatine aponeurosis	Posterior border of thyroid cartilage	Pharyngeal plexus	Elevates wall of pharynx, pulls palatopharyngeal arch medially